

## MDCT OF LIVER INJURY

Stuart E. Mirvis, MD, FACP

### Injury Classification

Increasingly blunt hepatic trauma is being managed nonoperatively. Many hepatic injuries are limited and are not bleeding at the time of surgery leading to nontherapeutic celiotomy with its costs and potential complications. CT has fostered this trend by demonstrating the extent of the injury, the presence or absence of concurrent intraperitoneal injuries, progression or resolution of the injury, and the development of complications such as infection or biloma. A surgical hepatic injury grading system developed through the AAST (Table 1) can estimate the extent of injury as can a CT-based grading system derived from the surgical system. Most studies indicate that all grade of hepatic can be successfully managed without surgery if the patient maintains hemodynamic stability and that therefore the grading of these injuries has no value in selecting patients for surgery or nonoperative management.

**TABLE 1: AAST SPLEEN INJURY SCALE**

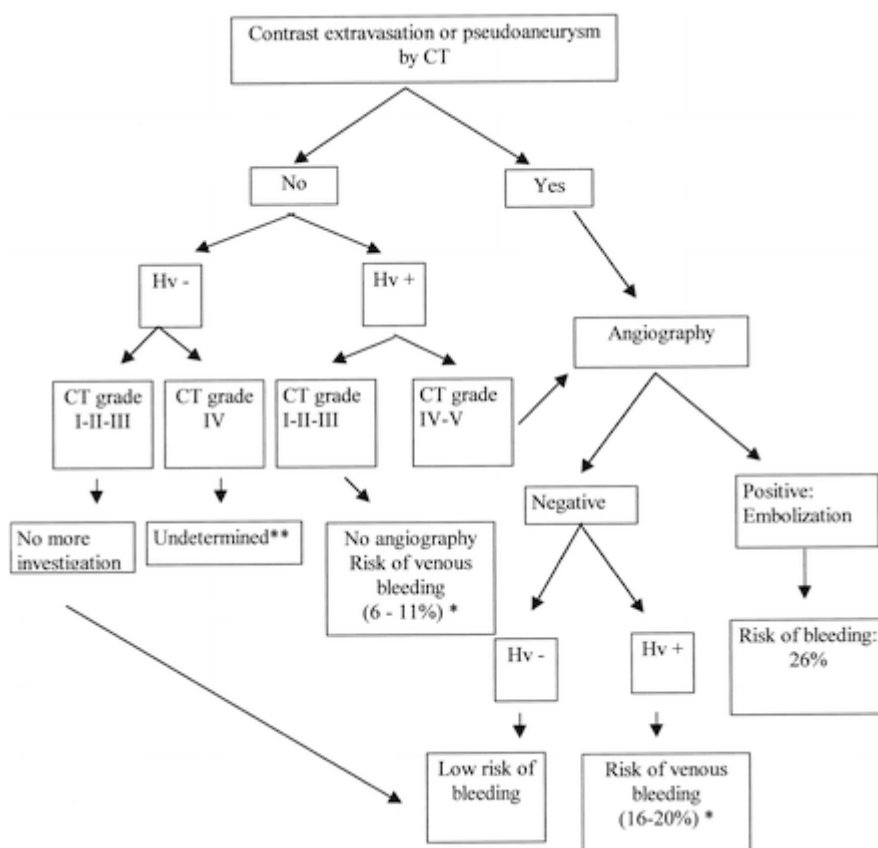
(1994 Revision)

GRADE*	TYPE	DESCRIPTION OF INJURY
I	Hematoma	Subcapsular, <10% surface area
	Laceration	Capsular tear, <1 cm parenchymal depth
II	Hematoma	Subcapsular, 10-50% surface area; Intraparenchymal, <5 cm in diameter
	Laceration	1-3 cm parenchymal depth which does not involve a trabecular vessel
III	Hematoma	Subcapsular, >50% surface area or expanding; ruptured Subcapsular or parenchymal hematoma
	Laceration	>3 cm parenchymal depth or involving trabecular vessels
IV	Laceration	Laceration involving segmental or hilar vessels producing major devascularization (>25% of spleen)
V	Laceration	Completely shattered spleen
	Vascular	Hilar vascular injury which devascularizes spleen

\* Advance one grade for multiple injuries, up to grade III

A prospective study of 63 patients with blunt hepatic injury conducted at the Maryland Shock-Trauma Center assessed clinical outcome with injury location.

All patients with positive CT results of CT Grade II or higher had hepatic angiography after CT (Flow Chart). The proximity of hepatic parenchymal injuries to the gallbladder fossa, porta hepatis, inferior vena cava, and major hepatic veins was analyzed. Injuries involving at least one major hepatic vein had a statistically increased association with failed nonoperative management and delayed hepatic-related complications. No other statistically significant correlation between site of injury and outcome of initial nonoperative treatment was found. In this study the presence of an arterial phase contrast blush was 65% sensitive and 85% specific for an arteriographically confirmed hepatic artery injury. This increased to 100% sensitive and 94% specific if only patients with CT grade II and III were considered. It was determined that patients with CT Grade I to III who did not have evidence of major hepatic vein involvement did not require hepatic angiography., while patients with CT Grade IV and V injury without an arterial blush, but with hepatic vein involvement did require angiography. In this study the need for operative or angiographic treatment of the liver increased with injury grade from II to V.



Flowchart depicts management algorithm for blunt hepatic trauma, based on CT and angiographic findings. *Hv+* = hepatic vein involved by the injury, *Hv-* = hepatic vein not involved by the injury. \* Indicated percentages are based on data from the current study only. The 6%-11% does not include the patients who underwent surgery, but the 16%-20% does. \*\* The patient sample in this group ( $n = 4$ ) was too small for statistical analysis. However, none of these four patients demonstrated further bleeding.

### Hepatic Vascular Injury

Intervention is required in patients with active bleeding in the liver, particularly if this bleeding occurs into a low pressure space as the peritoneal cavity or pleural space. If the patient is unstable hemodynamically and cannot be adequately resuscitated emergency surgery is required, perhaps using “damage control” techniques followed by angiographic intervention. Pseudoaneurysms that occur within liver injuries that extend to the capsule have a higher propensity for rupture and bleeding under or through the capsule and should be embolized.

Pseudoaneurysms that are surrounded by intact liver parenchyma may resolve without embolization and can be followed initially. If the aneurysm shows expansion or injury extension to the capsule then angiography with embolization is needed. Patients with traumatic hepato-biliary or hepato-venous fistulas also should undergo angiographic closure.

### **Biliary System Injury**

Injuries to the gallbladder are relatively uncommon occurring with less than 2% incidence in major blunt trauma. The spectrum of injury includes wall contusion, intraluminal hematoma, mucosal dissection, rupture, and partial or complete avulsion. CT signs of injury include deformation or collapse of the lumen, intraluminal high density blood clot, wall thickening, mucosal flaps projecting into the lumen, pericholecystic fluid, mass effect on the lateral duodenum, and ectopic location of the gallbladder. MDCT is usually adequate to delineate these injuries. In some cases when there is a question of a bile leak, hepatobiliary-scintigraphy is indicated. Associated injuries to the liver, duodenum and pancreatic head should be sought based on the focus of impact. Free rupture of the gallbladder wall requires cholecystectomy, but most other injuries will resolve without specific treatment. Liver lacerations that extend into the gallbladder fossa usually do not cause major gallbladder injury. Transhepatic lacerations that extend through the porta hepatis may injure the extra-hepatic biliary tree and hepatic scintigraphy is recommended. Collections of low attenuation bile in the porta hepatis or pericholecystic region also suggest bile duct injury.

**Selected references:**

1. Tzeng WS, Wu RH, Chang JM, Lin CY, Koay LB, Uen YH, Tian YF, Fong Y. Transcatheter arterial embolization for hemorrhage caused by injury of the hepatic artery. *J Gastroenterol Hepatol*. 2005 Jul;20(7):1062-8.
2. Contini S, Rubini P. Gallbladder injury in blunt abdominal trauma. *Surg Endosc*. 2001 Jul;15(7):757. Epub 2001 May 14.
3. Poletti PA, Mirvis SE, Shanmuganathan K, Killeen KL, Coldwell D. CT criteria for management of blunt liver trauma: correlation with angiographic and surgical findings. *Radiology*. 2000 Aug;216(2):418-27.
4. Dinkel HP, Moll R, Gassel HJ, Knüpfner J, Timmermann W, Fieger M, Schindler G. Helical CT cholangiography for the detection and localization of bile duct leakage. *AJR Am J Roentgenol*. 1999 Sep;173(3):613-7.
5. Erb RE, Mirvis SE, Shanmuganathan K. Gallbladder injury secondary to blunt trauma: CT findings. *J Comput Assist Tomogr*. 1994 Sep-Oct;18(5):778-84.
6. Howard R, Bansal S, Munshi IA. Biloma: a delayed complication of blunt hepatic injury. *J Emerg Med*. 2008 Jan;34(1):33-5. Epub 2007 Sep 17.
7. Taourel P, Vernhet H, Suau A, Granier C, Lopez FM, Aufort S. Vascular emergencies in liver trauma. *Eur J Radiol*. 2007 Oct;64(1):73-82. Epub 2007 Sep 12. Review.
8. DuBose J, Inaba K, Teixeira PG, Pepe A, Dunham MB, McKenney M. Selective non-operative management of solid organ injury following abdominal gunshot wounds. *Injury*. 2007 Sep;38(9):1084-90. Epub 2007 Jun 4.
9. Fang JF, Wong YC, Lin BC, Hsu YP, Chen MF. The CT risk factors for the need of operative treatment in initially hemodynamically stable patients after blunt hepatic trauma. *J Trauma*. 2006 Sep;61(3):547-53; discussion 553-4.
10. Yoon W, Jeong YY, Kim JK, Seo JJ, Lim HS, Shin SS, Kim JC, Jeong SW, Park JG, Kang HK. CT in blunt liver trauma. *Radiographics*. 2005 Jan-Feb;25(1):87-104. Review.