

CLINICAL MANAGEMENT OF PENETRATING TRAUMA

Karim Brohi, M.D.

The successful management of penetrating trauma relies on rapid diagnosis and prompt intervention. Injuries must be detected, and control achieved, without delay. There should be no unnecessary investigations and no unnecessary interventions.

Clinical examination is, in general, more reliable in penetrating than in blunt trauma. Many injury patterns can be fully assessed clinically, without any need for radiological or other assessment. Inappropriate radiological studies may delay definitive treatment. False negative studies can engender a false sense of security in clinicians and lead to delay in diagnosis. False positive studies may lead to unnecessary surgery.

Some injury patterns are not adequately evaluated by clinical examination alone. When the potential for such injuries exists, the appropriate investigation (and investigator) must be identified and should be available to the trauma team without delay. Clinical assessment is vital to this process, to direct the right investigation to the right patient at the right time.

Many injuries can now be managed entirely non-operatively. This avoids the complications of surgery and anaesthesia, and improves hospital efficiency. Non-operative management does not equate with conservative management. These patients should be nursed in a critical care area where physiologic and clinical parameters can be monitored regularly. Non-operative management relies on an adequate clinical examination. In situations where clinical examination is inadequate or compromised, further imaging and/or intervention are required to delineate and manage the injury.

Penetrating neck injury

Non-operative management is appropriate in many cases of penetrating neck injury. Decision-making focuses on the presence of clinical signs and symptoms, rather than penetration of the platysma muscle.

- No shock
- No expanding haematoma
- No evolving stroke

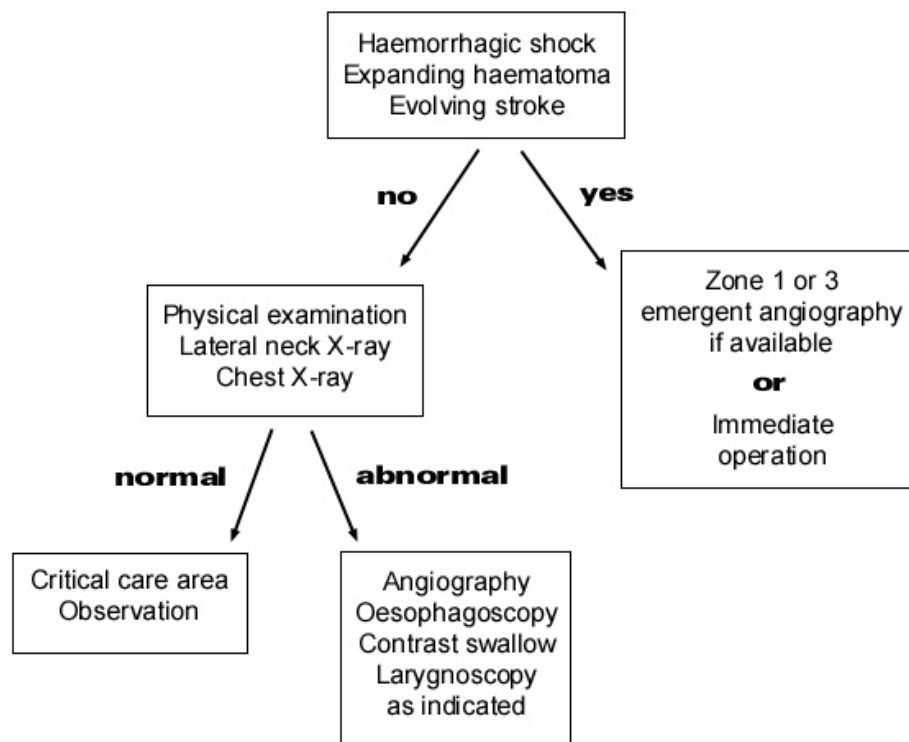
- No pain on swallowing
- No haemoptysis
- No subcutaneous emphysema
- No neurological deficit

Shock, expanding haematoma or evolving stroke imply injury to a major vascular structure. Injuries in Zone 2 of the neck are more amenable to surgical exploration than other neck zones. Zone 1 & 3 are best managed by

angiographic techniques or a combination of endovascular and open surgical techniques.

Oesophageal injury should be suspected if there is pain on swallowing, subcutaneous emphysema or soft tissue air on the lateral neck radiograph. A combination of contrast swallow and oesophagoscopy gives the maximum sensitivity and sensitivity in the assessment of oesophageal injury. The role of multidetector CT in penetrating neck injuries has not yet been determined.

Penetrating Neck Injury



References

Apffelstaedt JP, Muller R. Results of mandatory exploration for penetrating neck trauma. *World J Surg.* 1994 Nov-Dec;18(6):917-9

Sekharan J, Dennis JW, Veldenz HC, Miranda F, Frykberg ER. Continued experience with physical examination alone for evaluation and management of penetrating zone 2 neck injuries: results of 145 cases. *J Vasc Surg.* 2000 Sep;32(3):483-9

Eddy VA. Is routine arteriography mandatory for penetrating injury to zone 1 of the neck? Zone 1 Penetrating Neck Injury Study Group. *J Trauma.* 2000 Feb;48(2):208-13

Sofianos C, Degiannis E, Van den Aardweg MS, et al. Selective surgical management of zone II gunshot injuries of the neck: a prospective study. *Surgery.* 1996 Nov;120(5):785-8

Demetriades D, Theodorou D, Cornwell E, et al Evaluation of penetrating injuries of the neck: prospective study of 223 patients. *World J Surg.* 1997 Jan;21(1):41-7

Klyachkin ML, Rohmiller M, Charash WE, Sloan DA, Kearney PA. Penetrating injuries of the neck: selective management evolving. *Am Surg.* 1997 Feb;63(2):189-94

Demetriades D, Theodorou D, Cornwell E 3rd, et al. Penetrating injuries of the neck in patients in stable condition. Physical examination, angiography, or color flow Doppler imaging. *Arch Surg.* 1995 Sep;130(9):971-5

CT for penetrating neck injury

Gracias VH, Reilly PM, Philpott J, Klein WP, Lee SY, Singer M, Schwab CW. Computed tomography in the evaluation of penetrating neck trauma: a preliminary study. *Arch Surg.* 2001 Nov;136(11):1231-5

Munera F, Soto JA, Palacio D, Velez SM, Medina E. Diagnosis of arterial injuries caused by penetrating trauma to the neck: comparison of helical CT angiography and conventional angiography. *Radiology.* 2000 Aug;216(2):356-62

Mazolewski PJ, Curry JD, Browder T, Fildes J. Computed tomographic scan can be used for surgical decision making in zone II penetrating neck injuries. *J Trauma.* 2001 Aug;51(2):315-9

Penetrating Abdominal Trauma

Patients who present with penetrating abdominal trauma and who are in shock, have generalised peritonitis, or evisceration of abdominal contents should have an immediate laparotomy.

In some patients, there are multiple stab wounds or gunshot wounds with unknown trajectories. In these cases, when the patient is in shock, ultrasound or diagnostic peritoneal lavage may be helpful in identifying the abdomen as a site of major haemorrhage.

In the haemodynamically normal patient, options for investigation include physical exam and haemodynamic observation, diagnostic peritoneal lavage (DPL) and computed tomography (CT). Decisions on further investigation will vary depending on the available resources, the presence of other injuries and the conscious level of the patient.

CT may exclude peritoneal penetration and allow patients to be discharged immediately. However when there is peritoneal penetration, the diagnosis of hollow organ injury is currently less reliable by CT, and further investigation or observation is required.

Diagnostic peritoneal lavage is a very sensitive but non-specific test for abdominal penetration. However the non-therapeutic rate for DPL is high, as many abnormal findings are accounted for by omental & mesenteric injuries, or solid organ injury that requires no intervention.

Clinical observation has a high sensitivity and specificity for the management of penetrating abdominal trauma. However it is labour and resource intensive and may not be appropriate for all institutions. Additionally, it relies on the patient being awake, alert & cooperative, with no spinal cord injury or other 'distracting' injury.

Caution should always be exercised when dealing with thoracoabdominal or pelvic trauma, flank and back wounds, as the diaphragm and retroperitoneal structures are difficult to assess and injuries are easily missed.

References

Bishop M, Shoemaker WC et al. Evaluation of a comprehensive algorithm for blunt and penetrating thoracic and abdominal trauma. *Am Surg* 1991;57:737-46

Feliciano DV. Diagnostic modalities in abdominal trauma. Peritoneal lavage, ultrasonography, computed tomography scanning, and arteriography. *Surg Clin North Am* 1991;71:241-56

Marx JA Penetrating abdominal trauma. ; *Emerg Med Clin North Am* 1993;11:125-35

Peripheral Vascular Trauma

The diagnosis of significant vascular injury rests almost entirely in the physical examination. An absence of hard signs of vascular injury virtually excludes the presence of vascular trauma. In contrast, the presence of hard signs mandates immediate intervention.

Hard signs of Vascular Injury

- Pulsatile bleeding
- Expanding haematoma
- Absent distal pulses
- Cold, pale limb
- Palpable thrill
- Audible bruit

The presence of hard signs of vascular injury mandates immediate operative intervention. Usually the site of injury is obvious, and angiography is unnecessary. If in doubt, angiography can be performed emergently on the operating room table. Unnecessary interventions and investigations should be avoided to minimise the delay to definitive care.

So-called 'soft signs' of vascular injury are peripheral nerve deficit, history of moderate haemorrhage at scene, a reduced but palpable pulse or an injury in proximity to a major artery. Investigation or exploration of patients with soft signs alone is not warranted. Patients should be admitted and observed for 24 hours. Development of hard signs is rare, but mandates treatment as above.

High-velocity weapons, multiple fragment injuries and blunt trauma can make diagnosis less obvious, and angiography can be used to locate, or exclude, an injury.

Diagnostic Adjuncts

Pulse Oximetry

A reduction in oximeter readings from one limb, as compared to another is suggestive of, but neither confirms nor excludes a significant vascular injury. It is therefore essentially an unhelpful test.

Doppler Ultrasound

The diagnosis of a significant (ie. requiring intervention) vascular injury has been shown to be related to the presence or absence of a palpable pulse. The presence of a doppler signal in a pulseless limb only gives a false sense of security and does not imply a less severe or less urgent injury pattern.

A diminished, but palpable pulse is a soft sign of vascular injury. Similarly, a reduction in the ankle-brachial pressure index (ABPI) in the presence of a palpable pulse does not indicate the presence of a vascular injury requiring intervention. Doppler ultrasound therefore adds little to careful clinical examination.

Duplex Ultrasound

Duplex imaging is a non-invasive examination combining B-mode and Doppler ultrasound. It requires an experienced operator and is more operator-dependent. Duplex can detect intimal tears, thrombosis, false aneurysms and arteriovenous fistulae. Its place in the assessment of vascular injury is as yet not completely defined, but it has a high sensitivity and may be appropriate for use as a screening tool.

Angiography

Angiography remains the gold-standard investigation for the further investigation and delineation of vascular injury. In most traumatic injury settings, angiography is best performed in the operating room, with the surgeon exposing the vessel proximal to the injury for control and expediency.

Transfer to the radiology suite should be generally be restricted to haemodynamically stable patients either proximal or torso injuries. Angiography may be used to treat certain selected unstable injuries, where expertise and technical facilities are available. Proximal control may be possible with an angioplasty catheter prior to transfer to the operating room.

References

Frykberg ER. 'Advances in the diagnosis and treatment of extremity vascular trauma.' Surg Clin N Am 1995;75:207-223

EAST Practice Management Guidelines. 'Practice Management Guidelines for Penetrating Trauma to the Lower Extremity.' EAST 2001 <http://www.east.org/tpg/lepene.pdf>

Hafez HM, Woolgar J, Robbs JV 'Lower extremity arterial injury: results of 550 cases and review of risk factors associated with limb loss.' *J Vasc Surg* 2001;33:1212-1219

Britt LD, Weireter LJ, Cole FJ. 'Newer diagnostic modalities for vascular injuries: the way we were, the way we are.' *Surg Clin North Am.* 2001;81:1263-1279

Dennis JW, Frykberg ER, Veldenz HC et al. 'Validation of nonoperative management of occult vascular injuries and accuracy of physical examination alone in penetrating extremity trauma: 5- to 10- year follow-up.' *J Trauma* 1998;44:243-252

Miranda FE, Dennis JW, Veldenz HC et al. 'Confirmation of the safety and accuracy of physical examination in the evaluation of knee dislocation for injury of the popliteal artery: a prospective study.' *J Trauma* 2002;52:247-252